Ocular Trauma

Dr. Dunera R. Ilako

25 July 2003

UON Year III

Expectations

- What caused injury
- Which part of eye injured
- What kind of injury
- First line treatment
- What treatment
- When to treat
- When to refer!

Ocular Trauma

- Morbidity
- Psychological
- Cosmetic

Trauma

- Epidemiology
- Terminology and Classification
- Evaluation
- Anaesthesia
- Management - Cornea & Iris
- Medicolegal issues

Ocular Trauma Classification

A. Rupture
B. Penetrating
C. IOFB
D. Perforating
E. Mixed

Grade (Visual acuity)

A. ≥20/40
B. 20/50 to 20/100
C. 19/100 to 5/200
D. 4/200 to light perception
E. NLP

Pupil

A. Positive, relative APD in injured eye
B. Negative, relative APD in injured eye

Zone (see Fig. 2–1)

I. Cornea and limbus
II. Limbus to 5 mm posterior into sclera
III. Posterior to 5 mm from the limbus



Kuhn F et al,Ophthalmol'96

Epidemiology

- US Eye Injury Registry
  - 51 % Serious ocular trauma
  - 59 % Of Globe Lacerations
  - 30 % Iris Laceration

Evaluation

- Clinical
  - History
  - Examination
  - Hyseria/Malingering
  - Transportation of eye-injured patient
- Diagnostic imaging
  - Plain X rays
  - CT- Scans
  - Ultrasound
  - MRI

Preparation for surgery

- Minimise risk of further injury
- Maximise surgical success
- Decrease risk to patient health
- Minimase pschic trauma
- Mimise risk of legal involvement
- Preoperative check list

Mechanism of Injury

- Mechanical
- Chemical
- Physical agents
- Indirect ocular trauma

Mechanical

- Eyelid injuries
- Lachrymal system
- Conjuntival lacerations
- Foreign bodies (cornea, conjunctiva)
- Corneal erosions
- Nonpenetrating injury
- Penetrating
- Blowout fracture

Eyelid Haematoma

subconjunctival haemorrhage

Basal skull fracture - bilateral ring haematomas (‘panda eyes’)

Lid margin laceration/Lid avulsion

Lid margin laceration repair

Carefully align to prevent notching

Align with 6-0 black silk suture

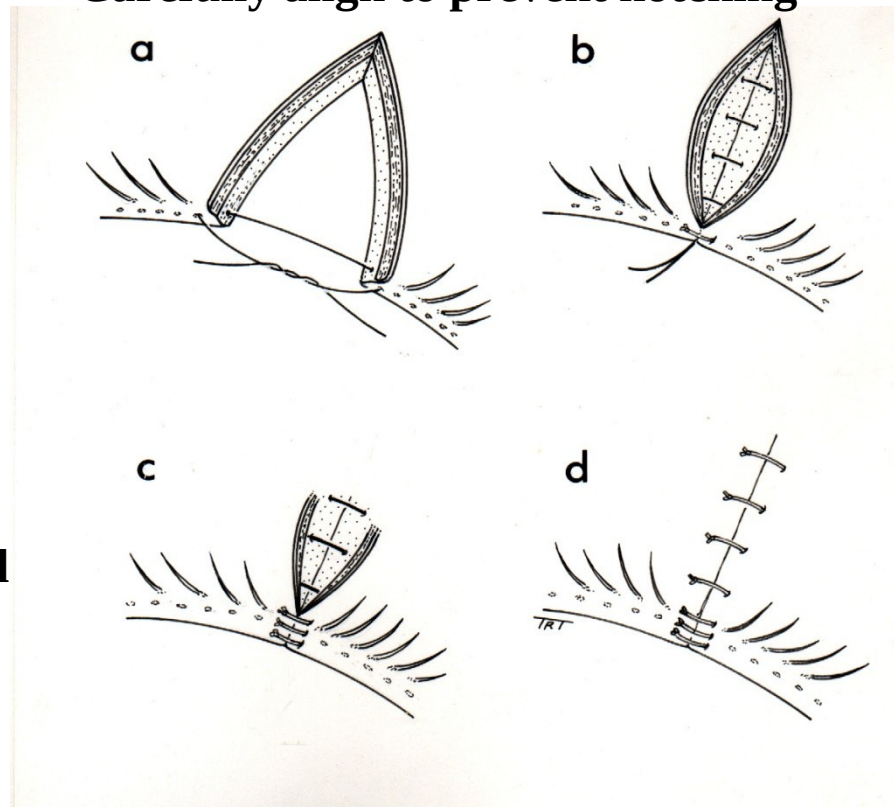

Close tarsal plate with fine absorbable suture

Place additional marginal silk sutures

Close skin with multiple interrupted 6-0 black silk sutures

CONT.

- In a nasal eyelid avulsion the punctum may be lost.
- Destruction of the canaliculi results in impaired drainage.

Canalicular laceration

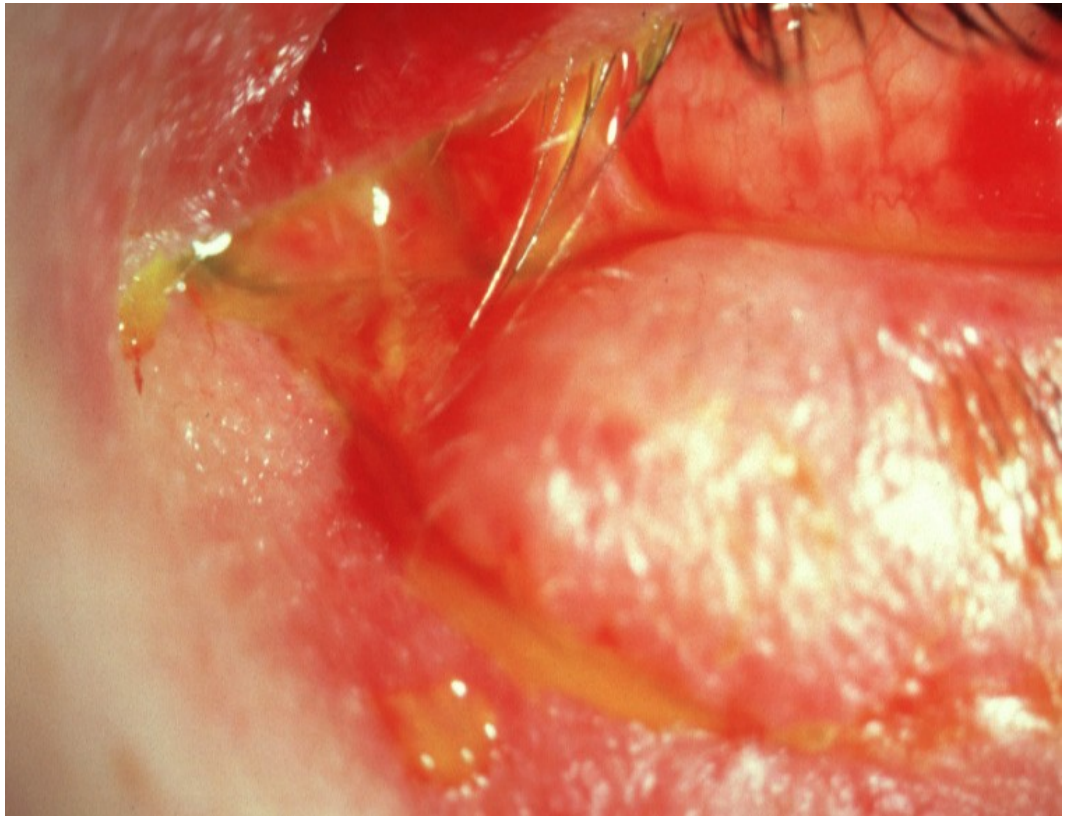

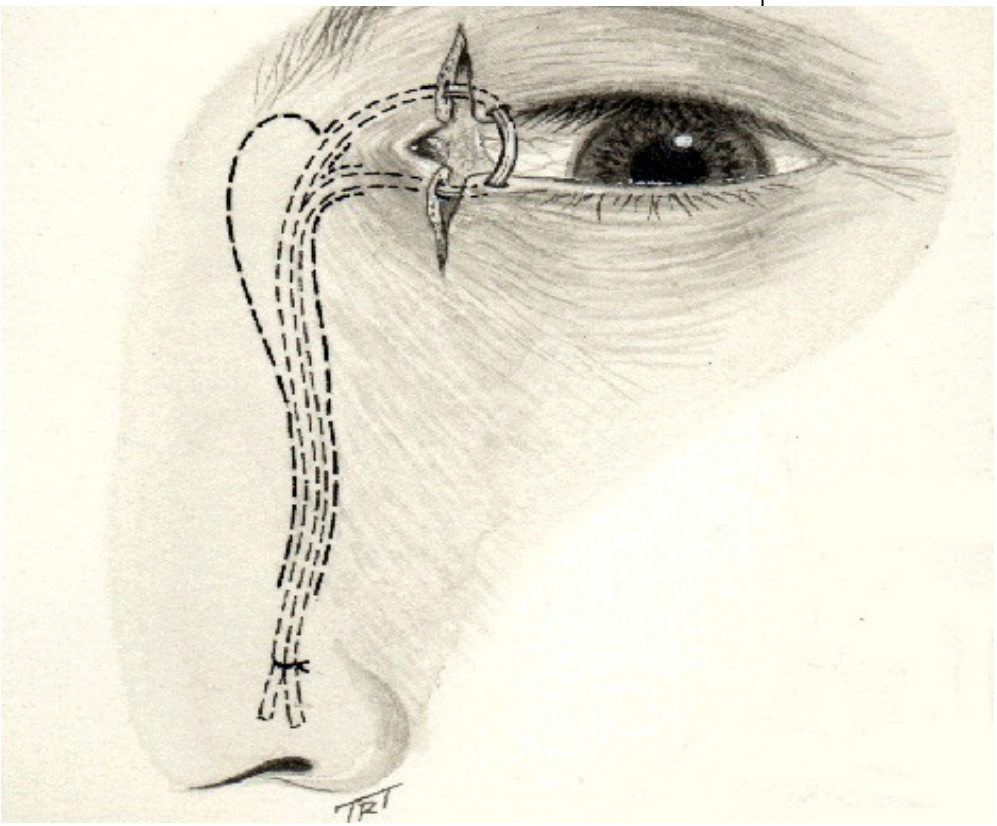

- **Repair within 24 hours**

- **Locate and approximate ends of laceration**
- **Bridge defect with silicone tubing**
- **Leave *in situ* for about 3 months**

Blow Out Fractures

Pathogenesis:orbital floor blow-out fracture

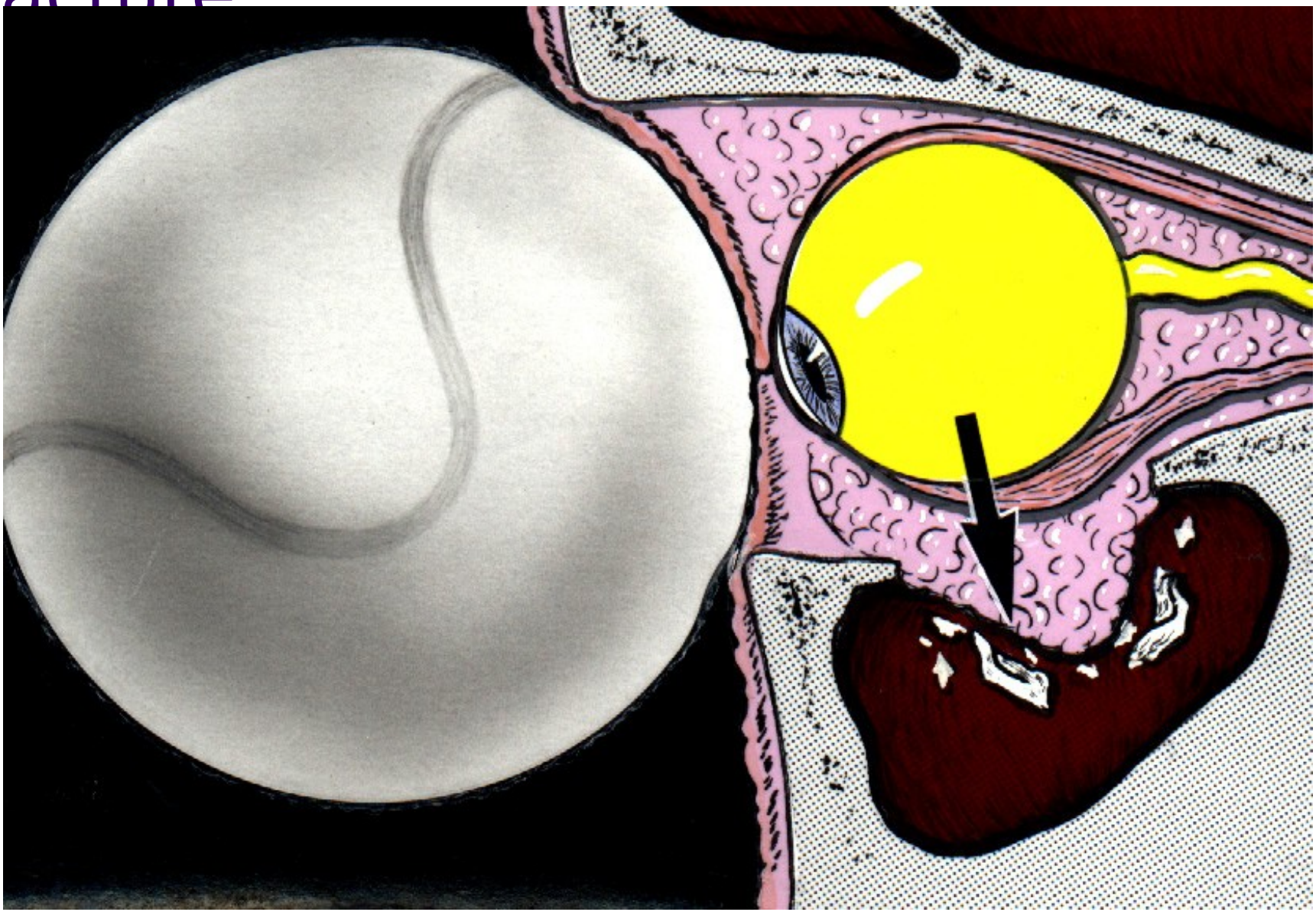

Signs of orbital floor blow-out fracture

- **Peri-ocular ecchymosis and edema**
- **Infraorbital nerve anaesthesia → indication for surgery**
- **Smaller fissure height in the right eye**

- **Ophthalmoplegia - typically in up- and down-gaze (double diplopia)**

- **Enophthalmos - if severe**
- **(Worm's eye view)**

Investigations:orbital floor blow-out fracture

Coronal CT scan

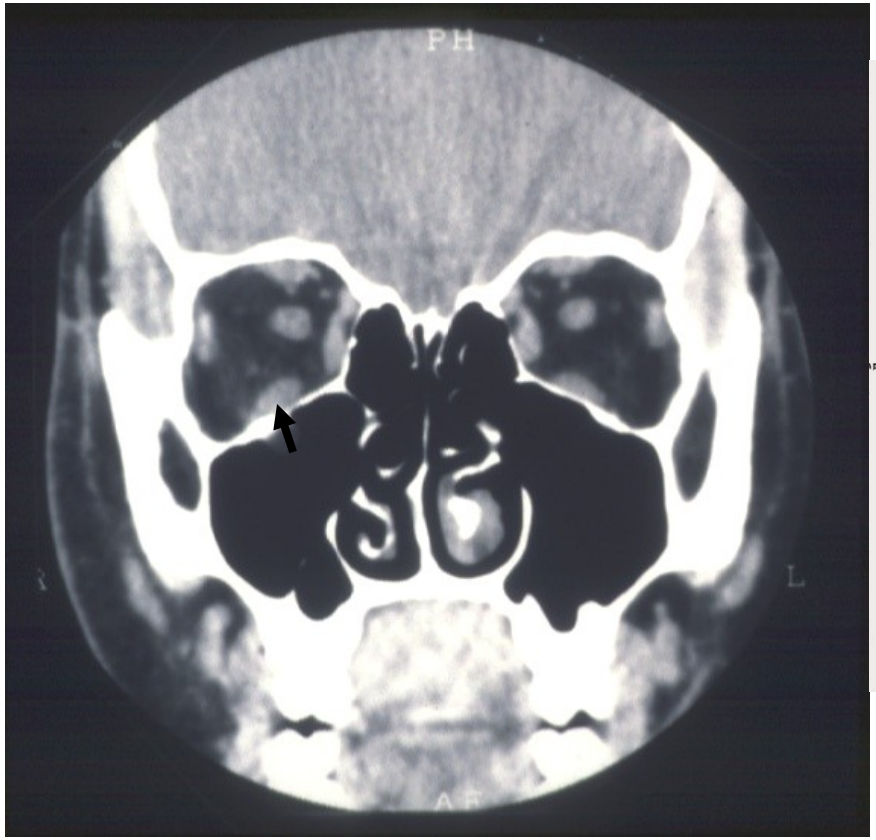

Hess test

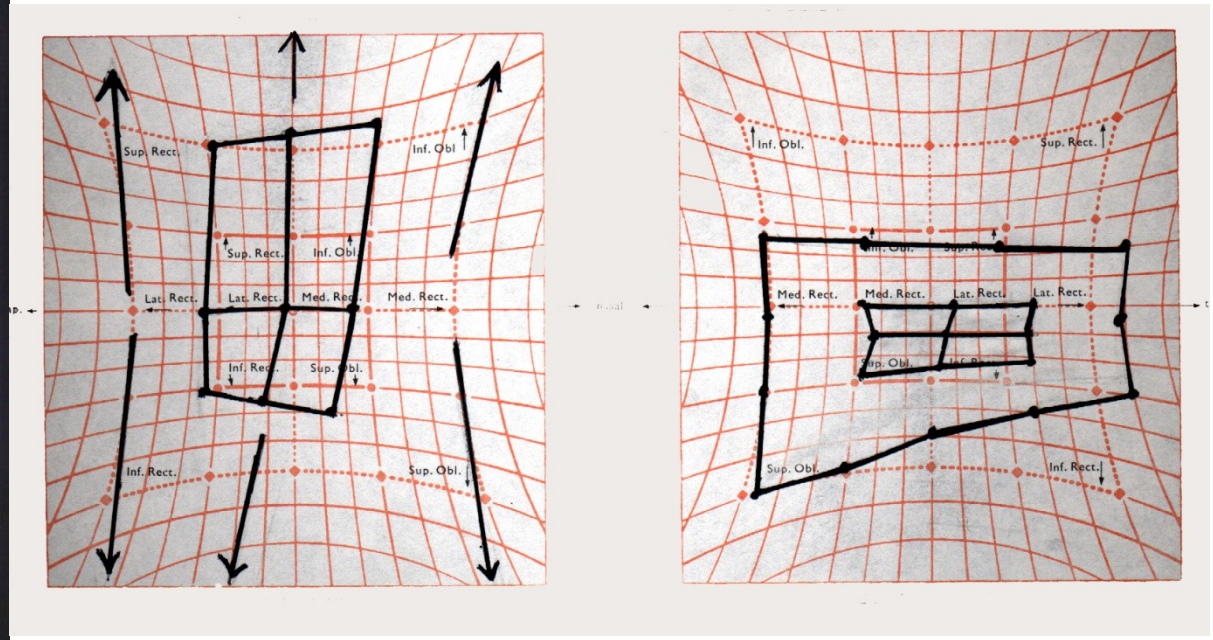

- **Right blow-out fracture with ‘tear-drop’ sign**

- **Restriction of right up gaze and down gaze**
- **Secondary overreaction of left eye**

Medial wall blow-out fracture

Signs

Periorbital subcutaneous emphysema

Ophthalmoplegia - adduction and abduction if medial rectus muscle is entrapped

Treatment

- **Release of entrapped tissue**
- **Repair of bony defect**

- Penetrating Eye Inyuries

Open globe injury

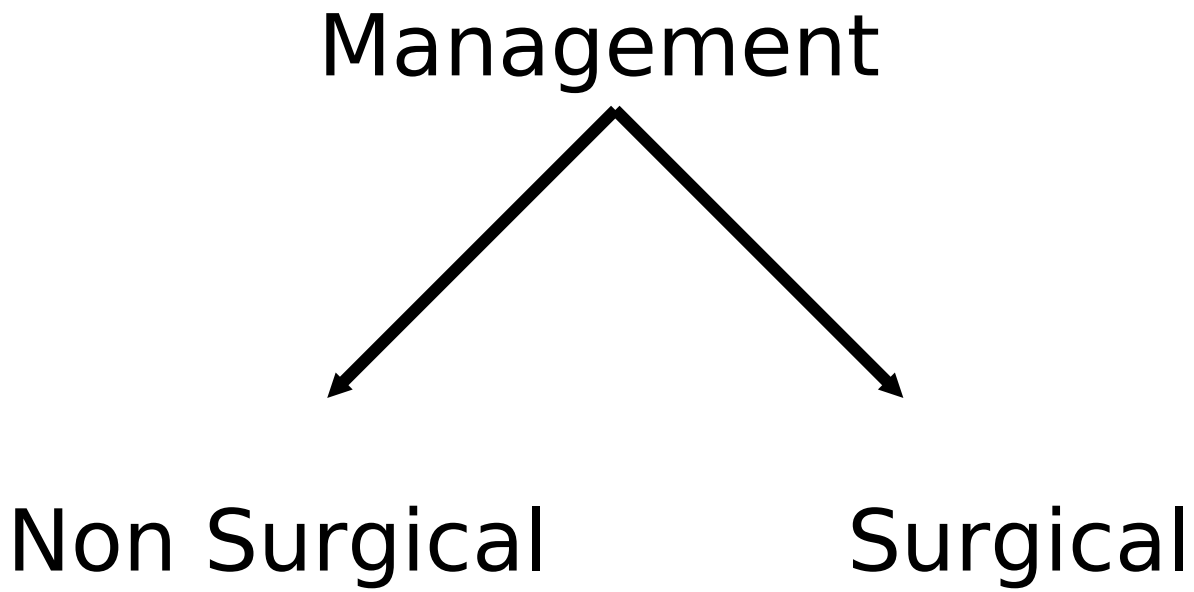

Open globe injury

- Nonsurgical Treatment
  - Bandage contact lens
  - Cyanoacrylate tissue adhesive
  - Topical antibiotics

Open globe injury

- Anaesthesia
  - General anaesthesia
  - Modified Retrobulbar injection

    Mikel L et al,Am J Opthalmol 1997
  - Laryngeal mask

Complications of penetrating trauma

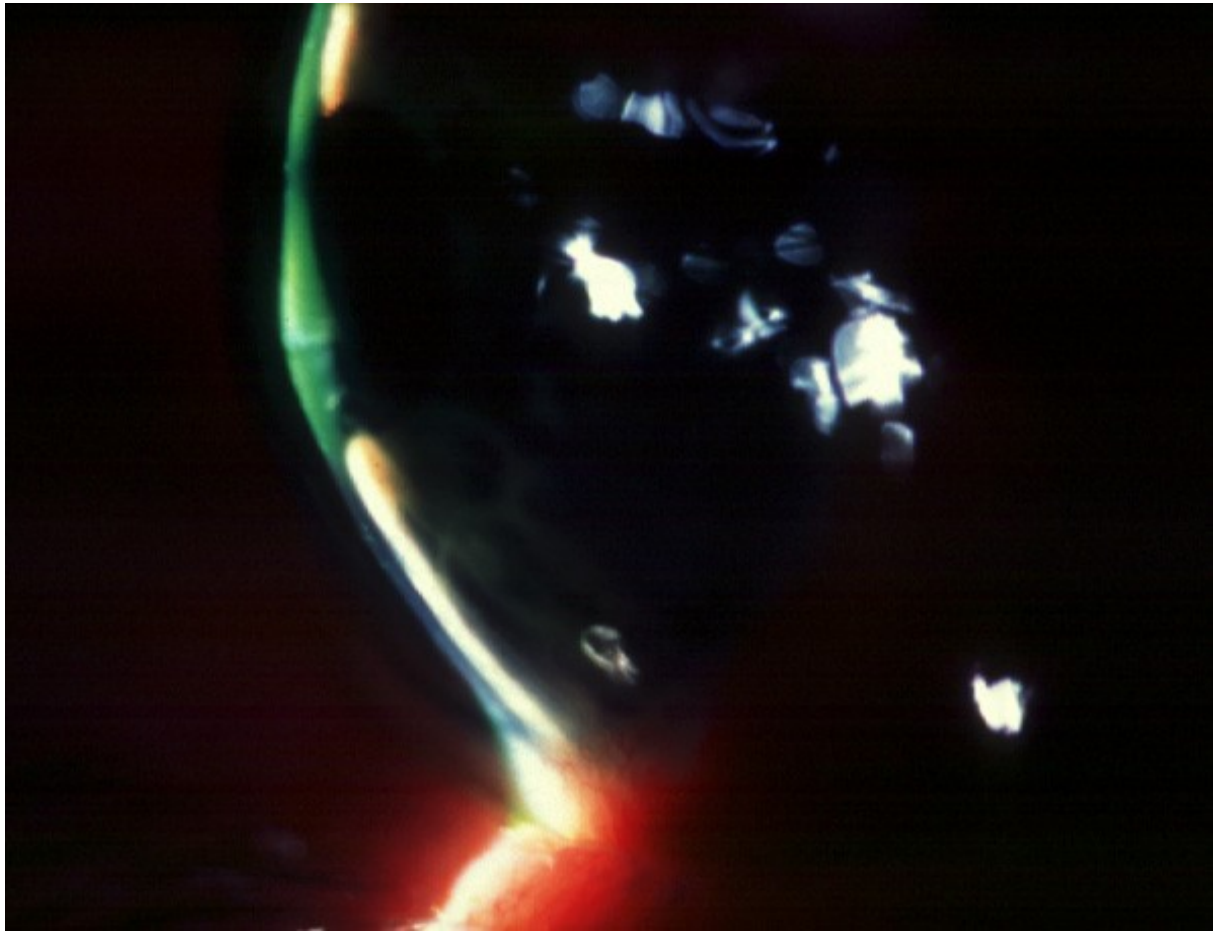

Flat anterior chamber

Complications of penetrating trauma.....

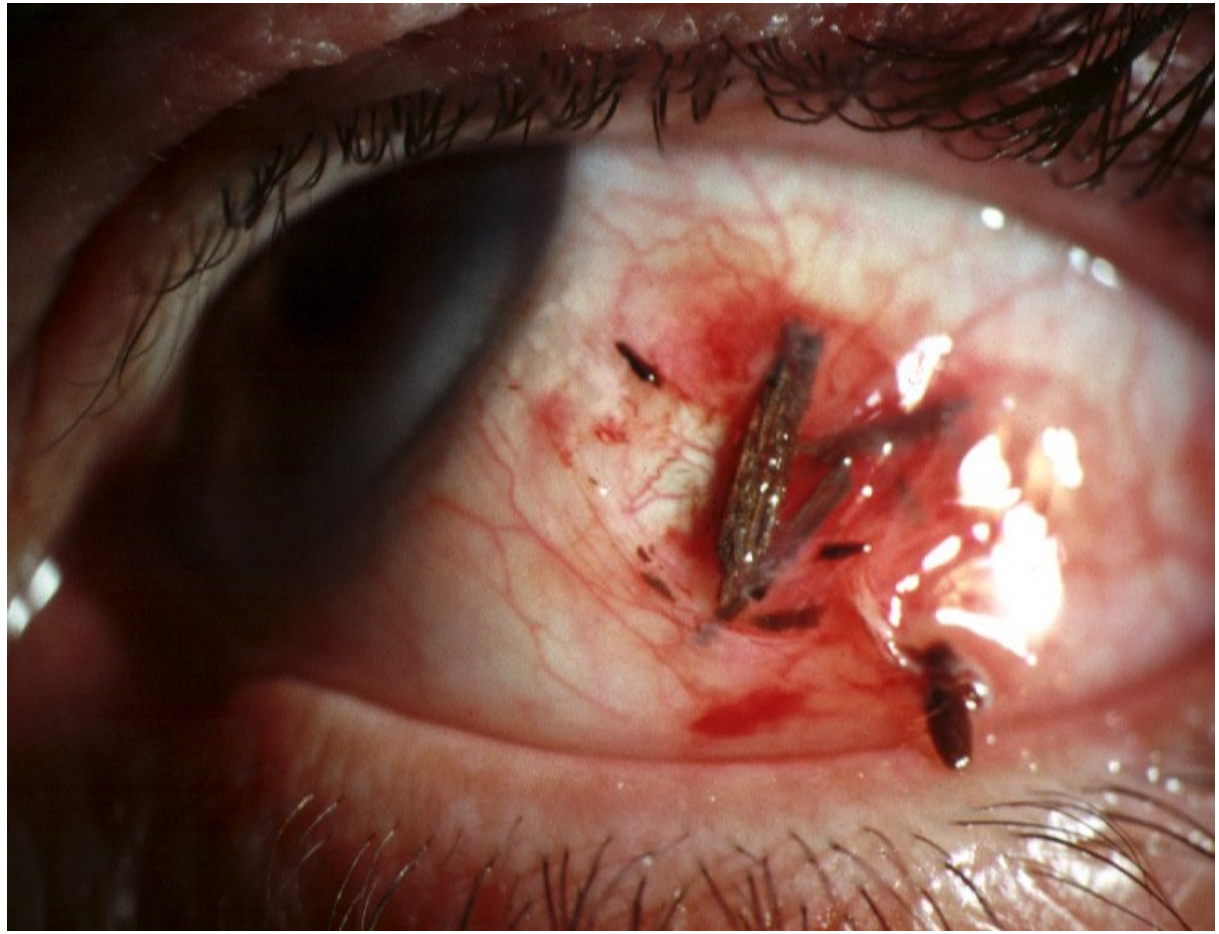

Uveal prolapse

Complications of penetrating trauma…….

Damage to lens and iris

Complications of penetrating trauma……

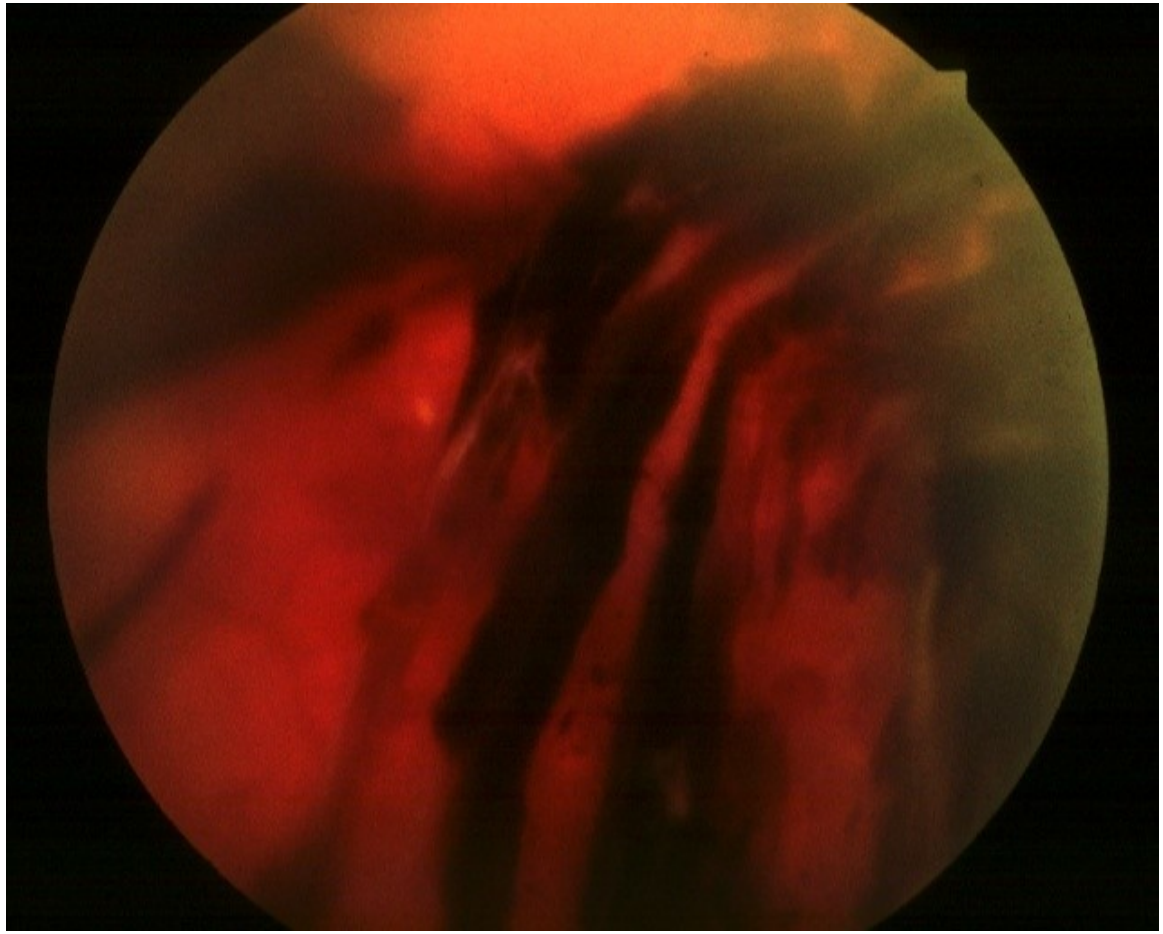

Vitreous haemorrhage

Raptured globe

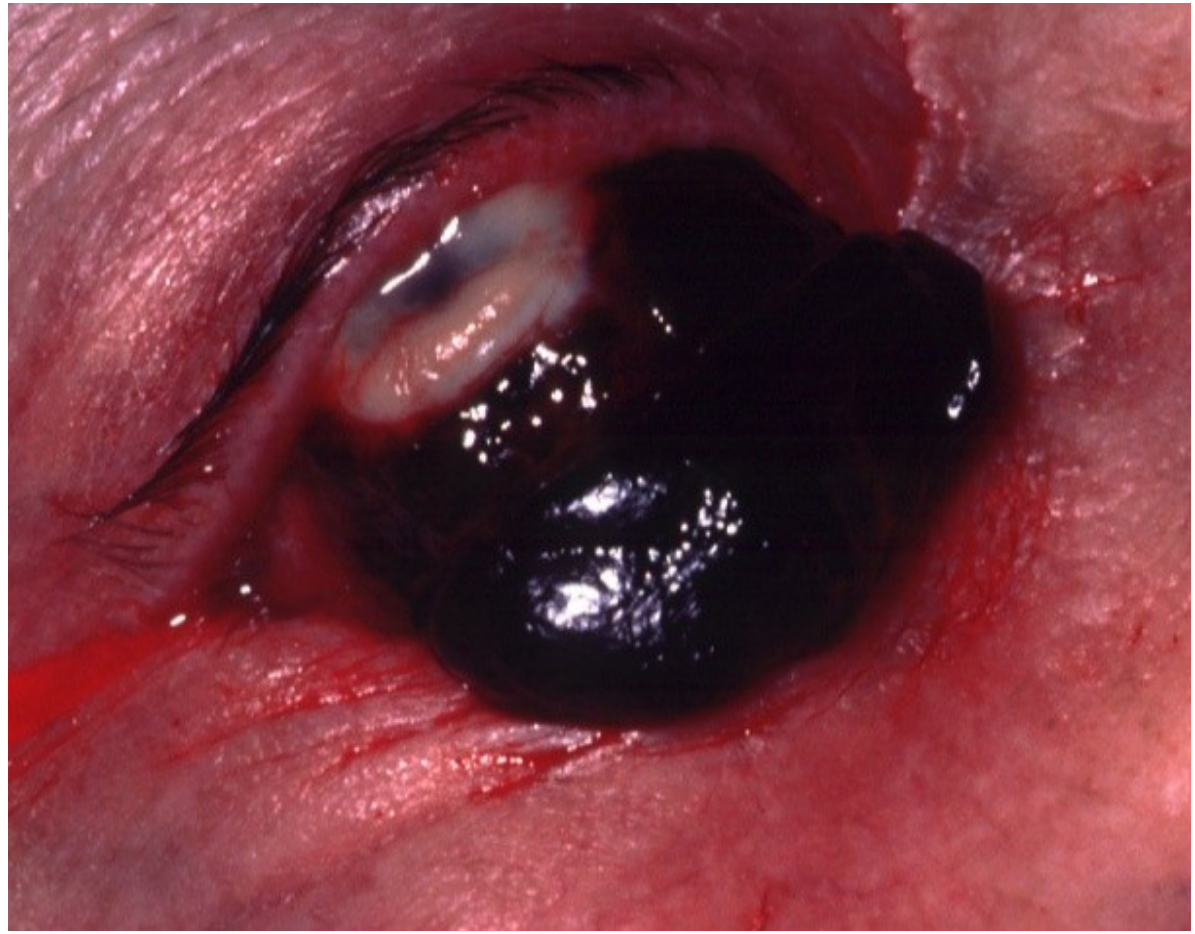

Raptured globe: Management

- Repair
- Enucleation
- Eviseration

Complications of penetrating trauma…….

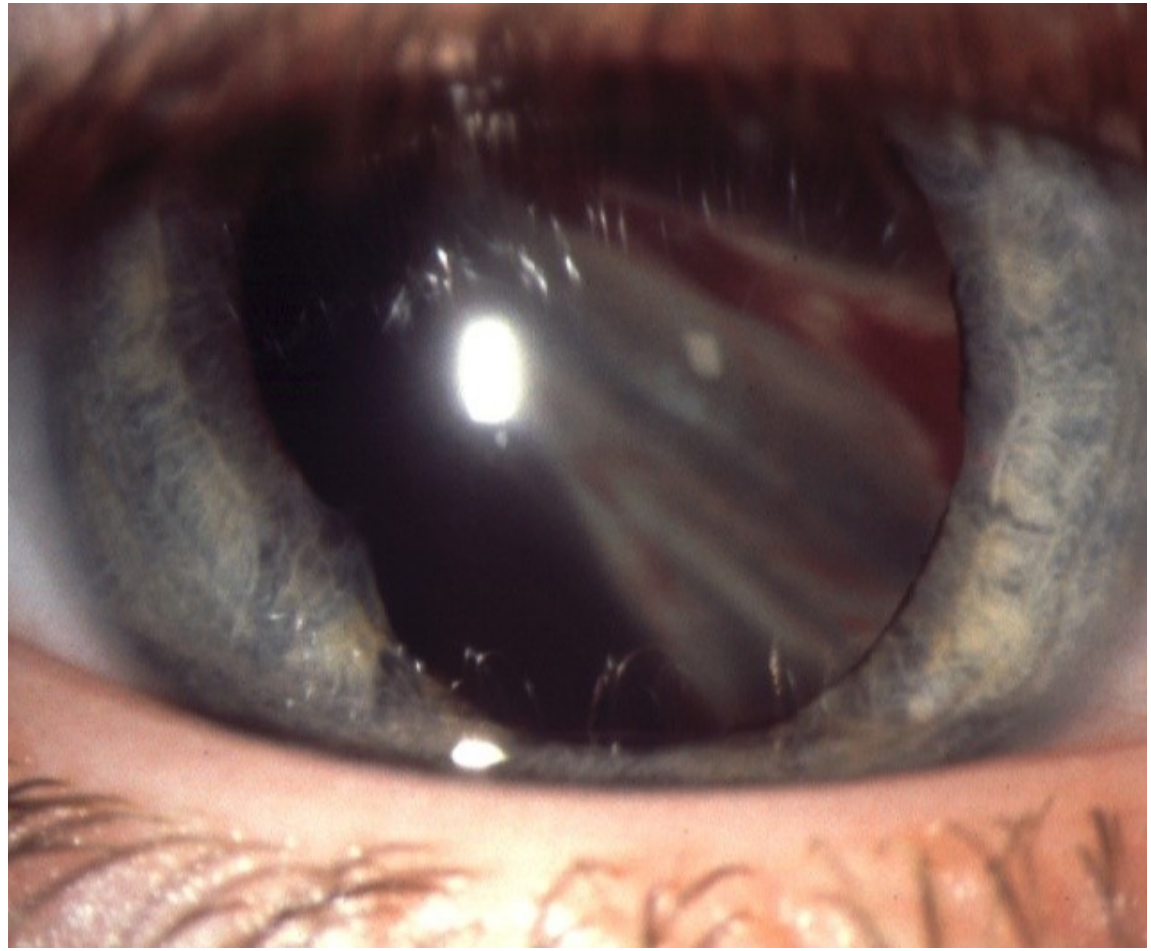

Tractional retinal detachment

Complications of penetrating trauma…….

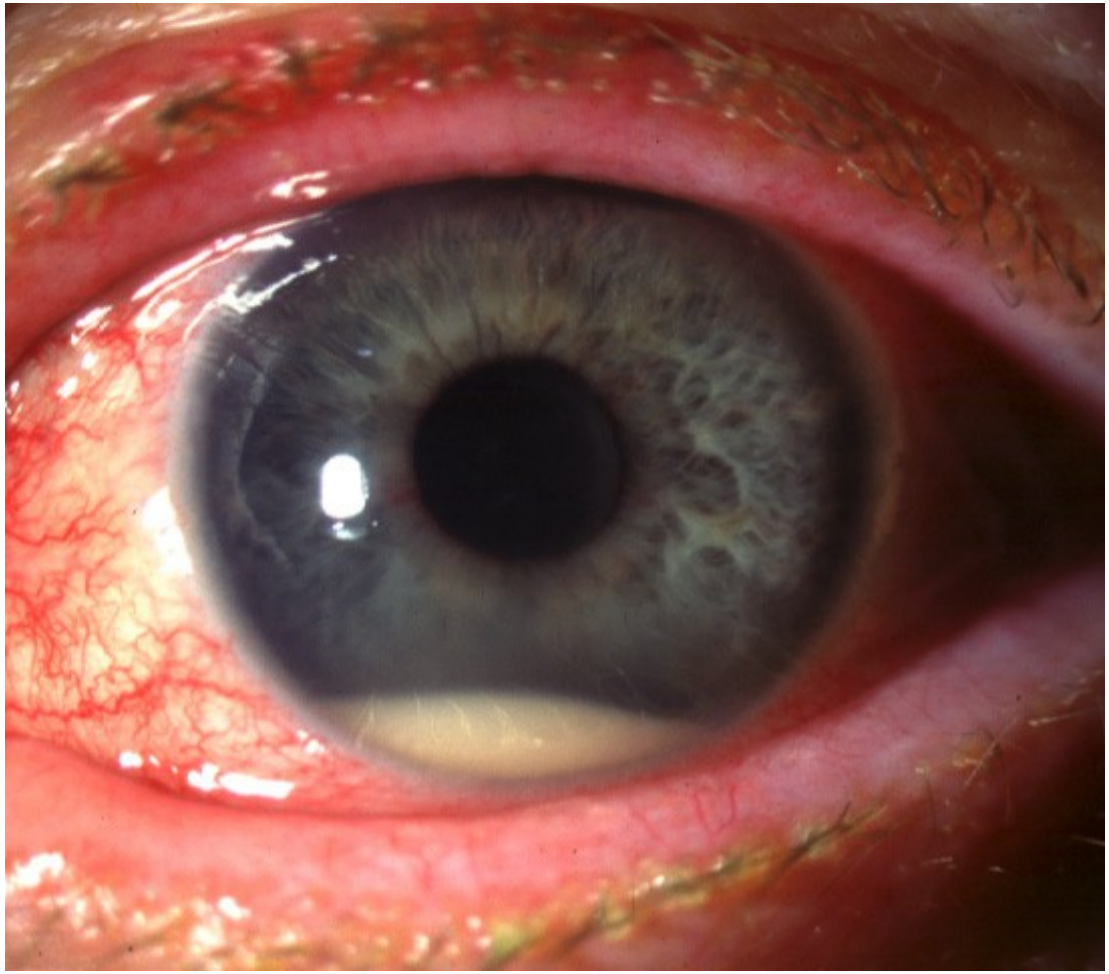

Endophthalmitis

Corneal Perforation

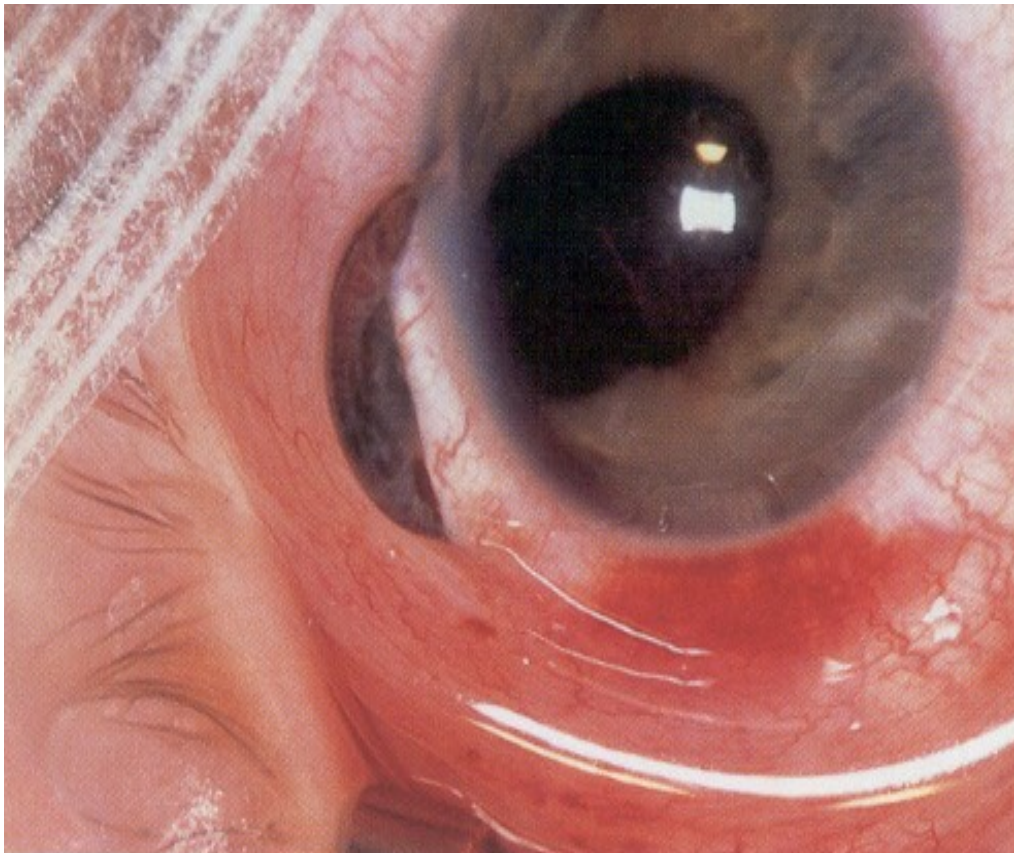

Corneal Trauma

- Goals
  - Restoration of Structural Integrity
  - Prevention of Post Operative astigmatism

If You Can’t, Don’t !!

Management of corneal

- Eye shield
- Tetanus prophylaxis
- Antibiotics
  - Topical
  - Intravenous antibiotics
    - Cefazolin,Gentamicin
    - Clindamycin
  - Oral: Ciprofloxacin

Management

- History
- Evaluation
  - Visual Acuity by Physician
  - Preservative Free Lidocaine
- Rule out IOFB
- Confounding factor
- Therapeutic plan

- *Pause*

Anterior segment complications of blunt trauma

INCLUDE

- Hyphaema
- Sphincter tear
- Iridodialysis
- Vossius ring
- Cataract
- Lens subluxation
- Angle recession
- Rupture of the globe

Hyphaema



Hyphaema.....



- Causes/demographics
  - M:F 3:1, 70%< 20 years
  - Blunt injury: (fist,rocks,sticks,sport etc)
  - Spontaneous: rare, blood dyschrasia, SCD
- Grading;
  - Microscopic: circulating RBCs only
  - I < 1/3
  - II 1/3 - ½
  - III ½ - 2/3
  - IV Total

Hyphaema.....



- Treatment
  - Grade I/II as outpatient.
    - Bed rest
    - Daily follow up: Monitor; VA, IOP,amount of hyphaema
  - Grade III/>: Admit
    - Surppotive:
      - Monitor: VA, IOP, level of hyphema,cornea staining
      - Elevate head 45 degrees
      - Eye sheild
    - Medical treatment
      - Cycloplegics
      - Topical steroids
      - Analgesics
      - Antiglaucoma treatment

Hyphaema.....



- Surgical intervention
  - Indications
    - IOP: >50mmHg for 5 days or >35 mmHg for 7 days
    - Corneal blood staining and if compromised endothelial function
    - Prolonged clot duration: >10 days
  - Techniques
    - A/C washout
- Complications
  - Rebleeding
  - Glaucoma
  - Corneal staining

Sphincter tears/Iris Laceration

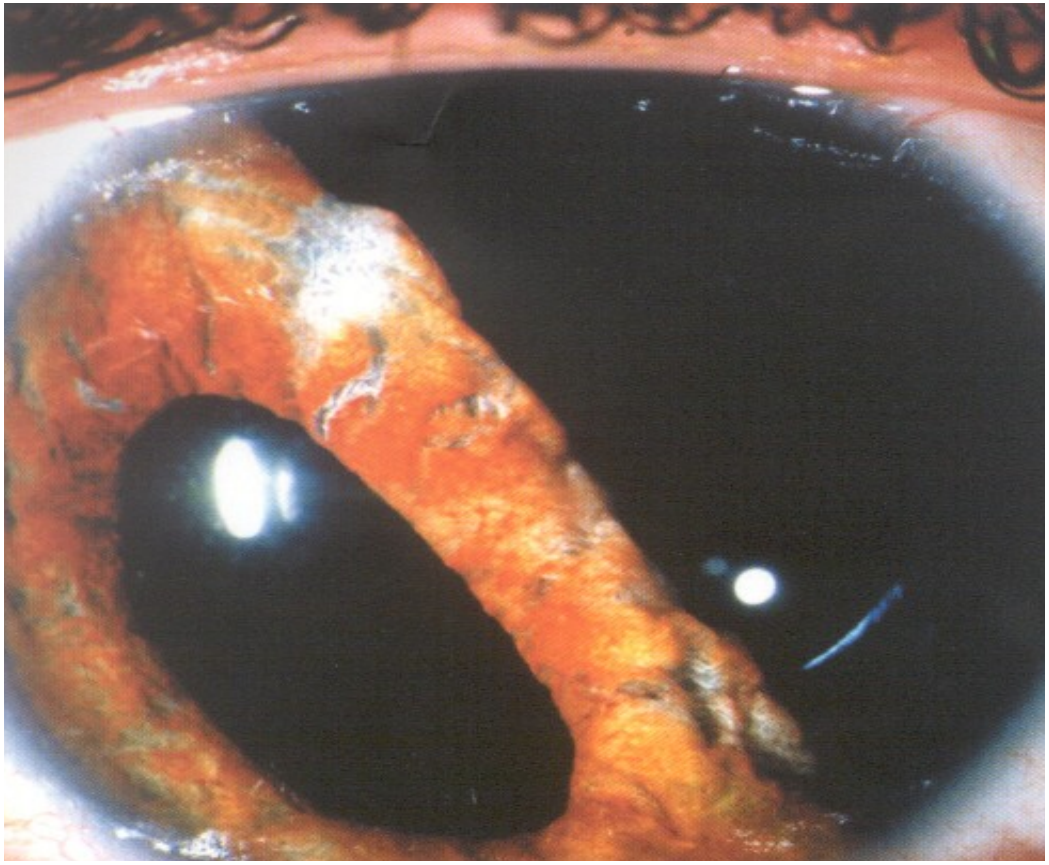

Iridodyalysis

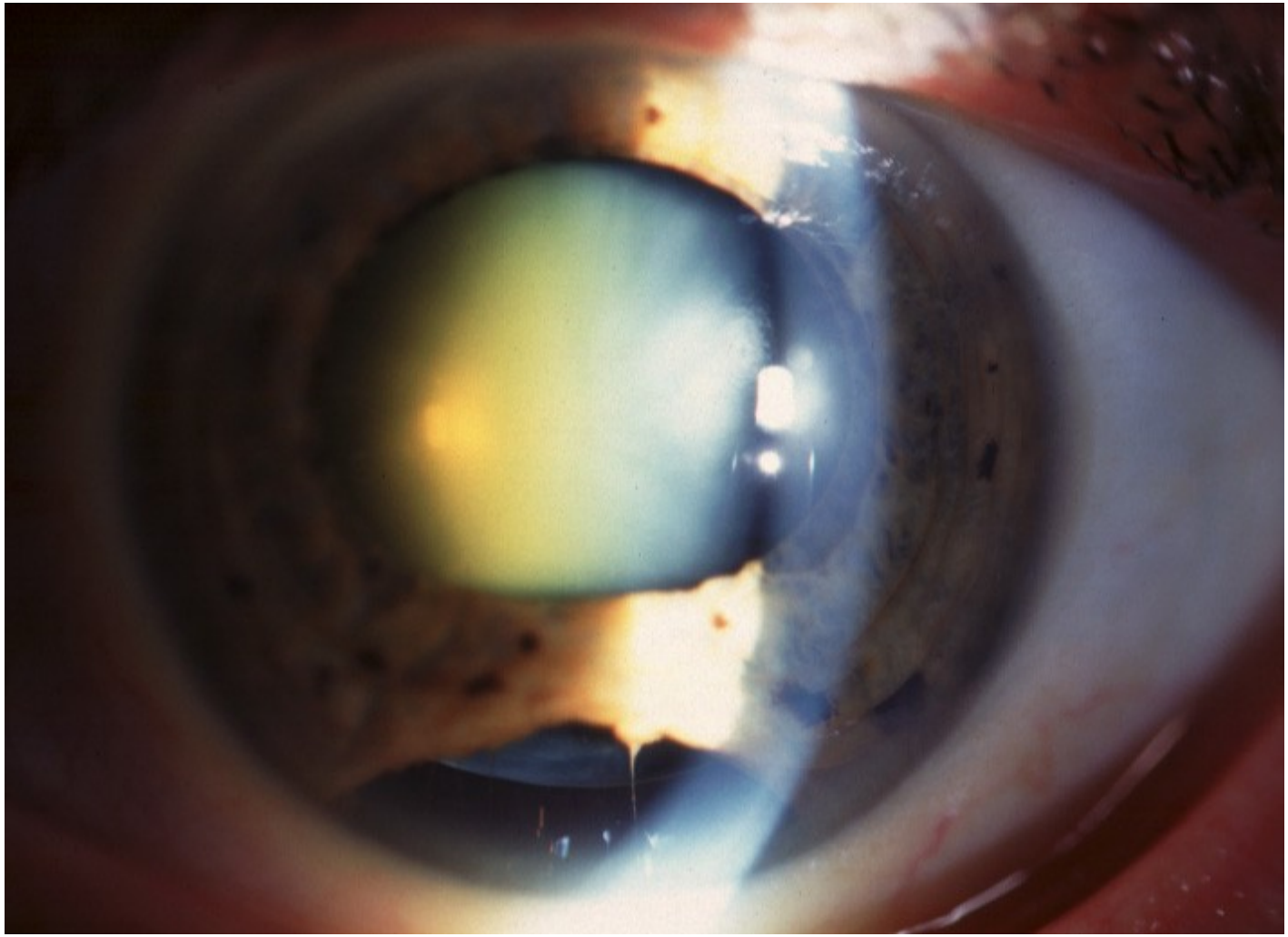

Vossius Ring

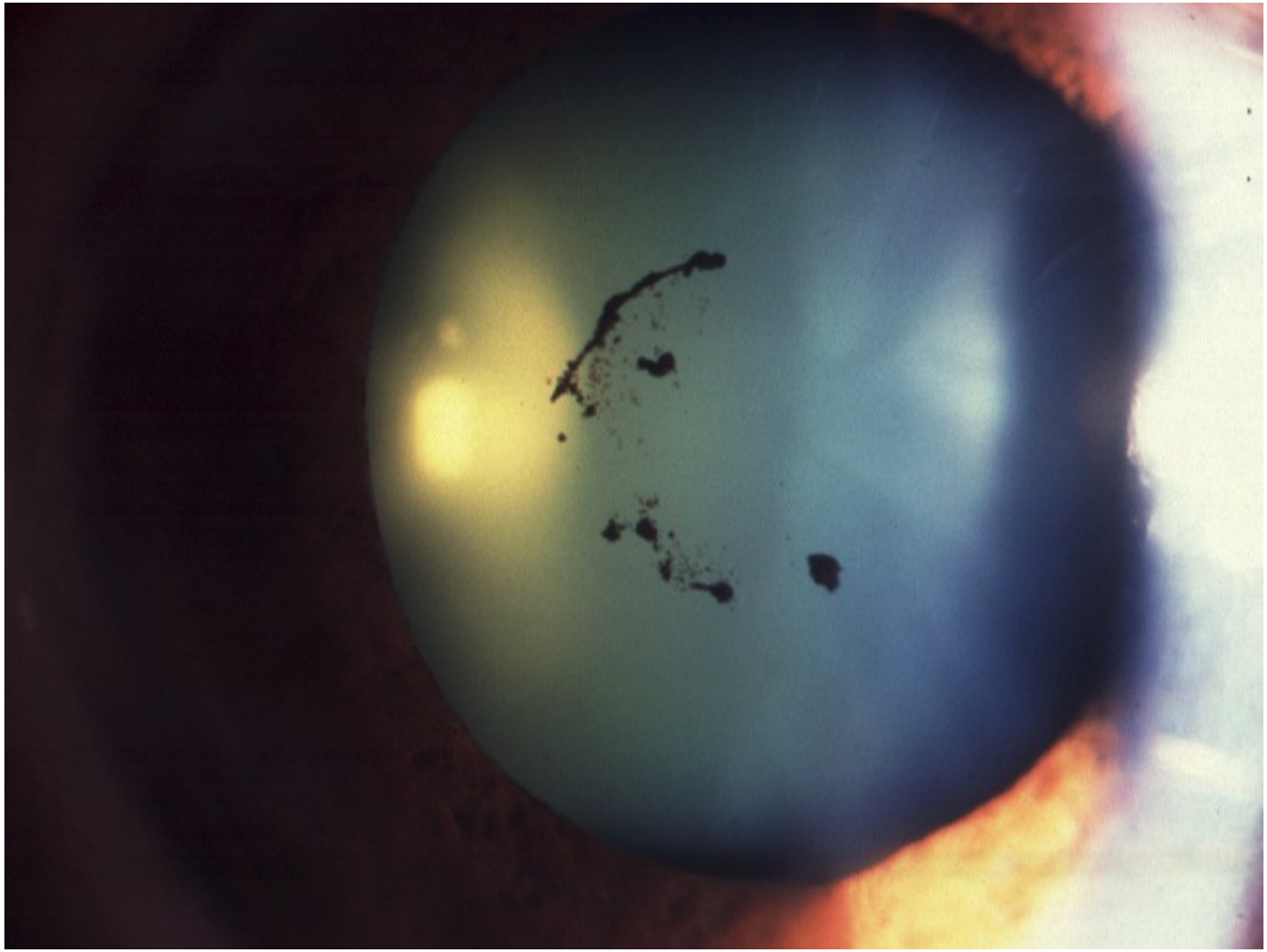

Cataract

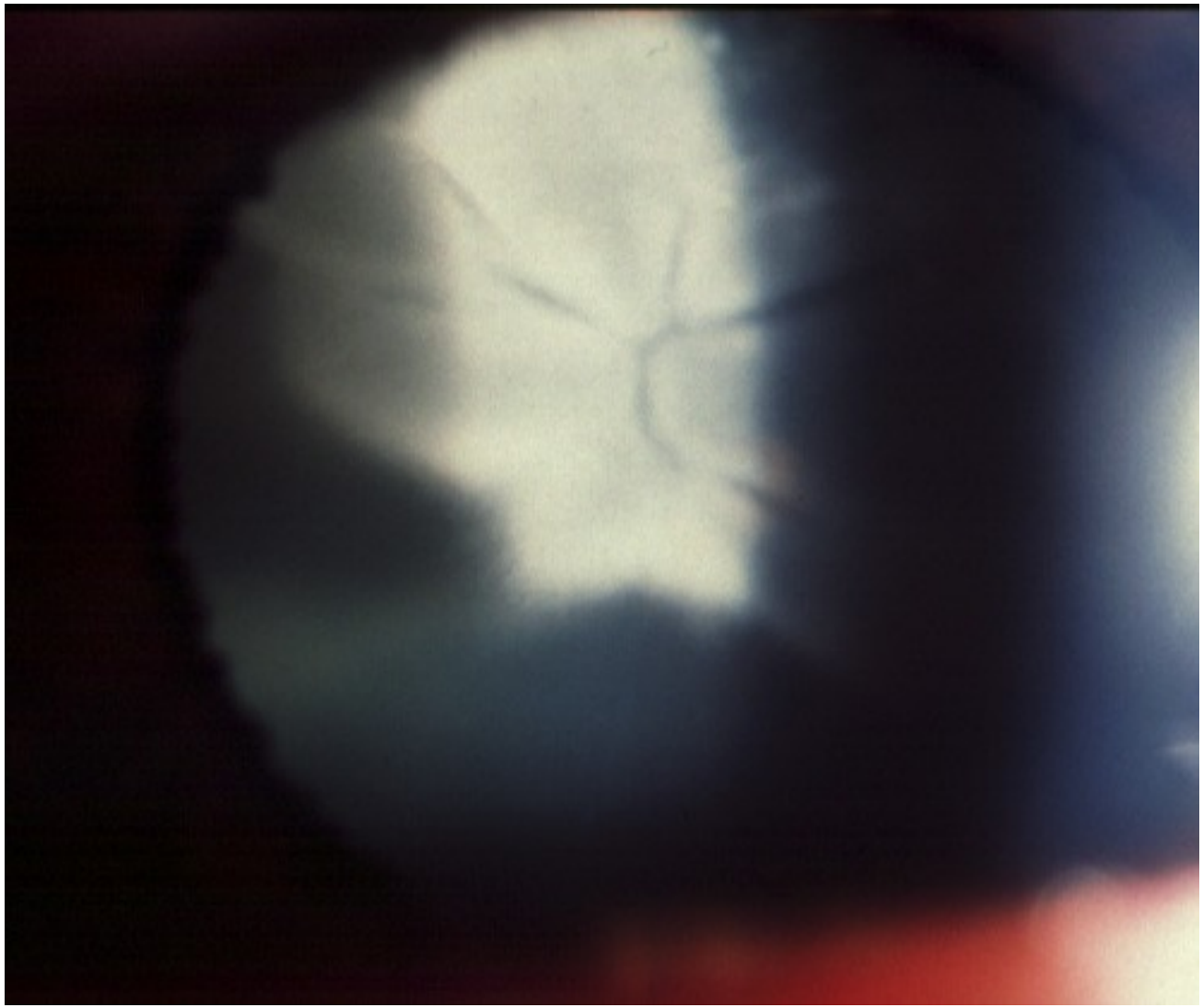

Lens Sublaxation

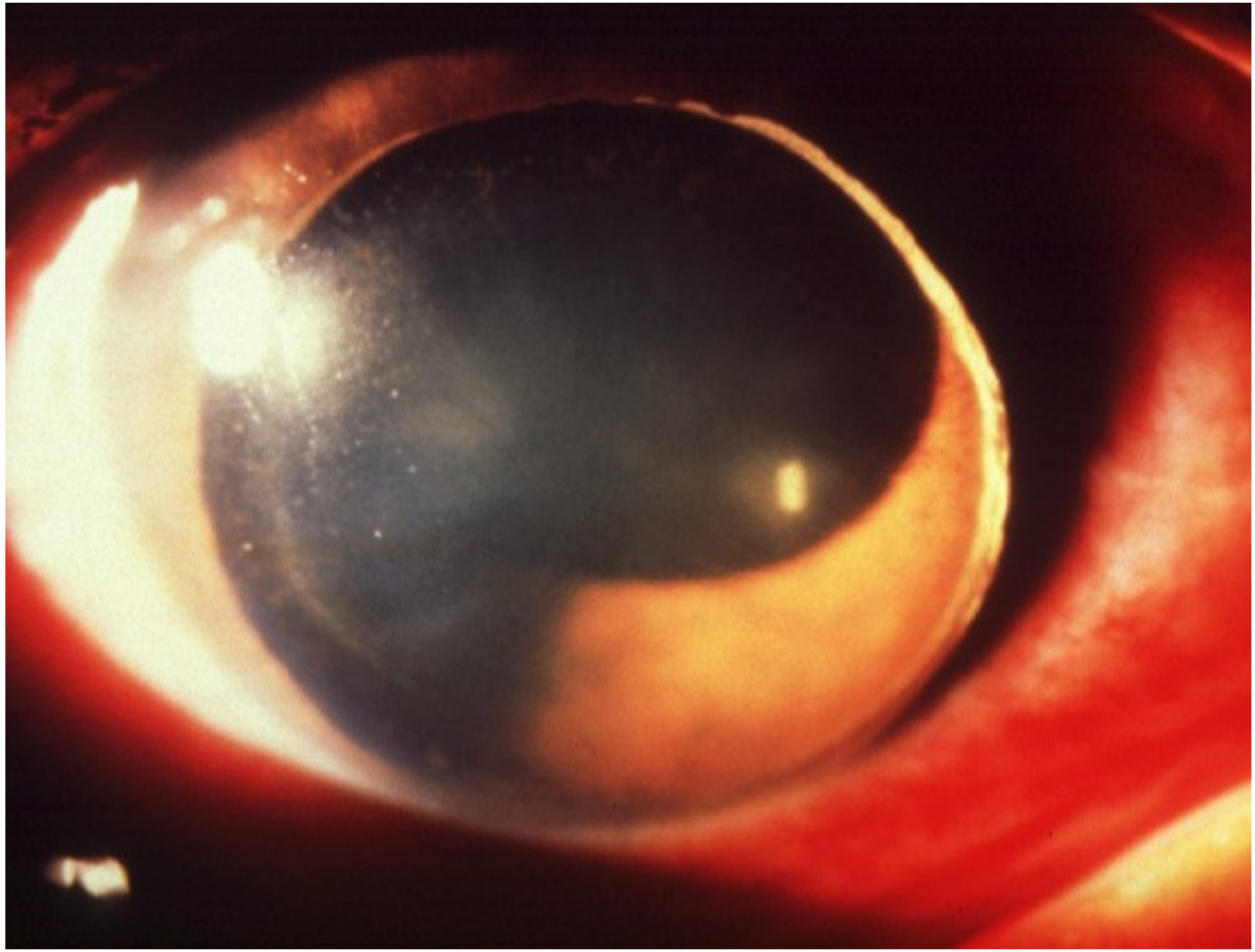

Angle recesion

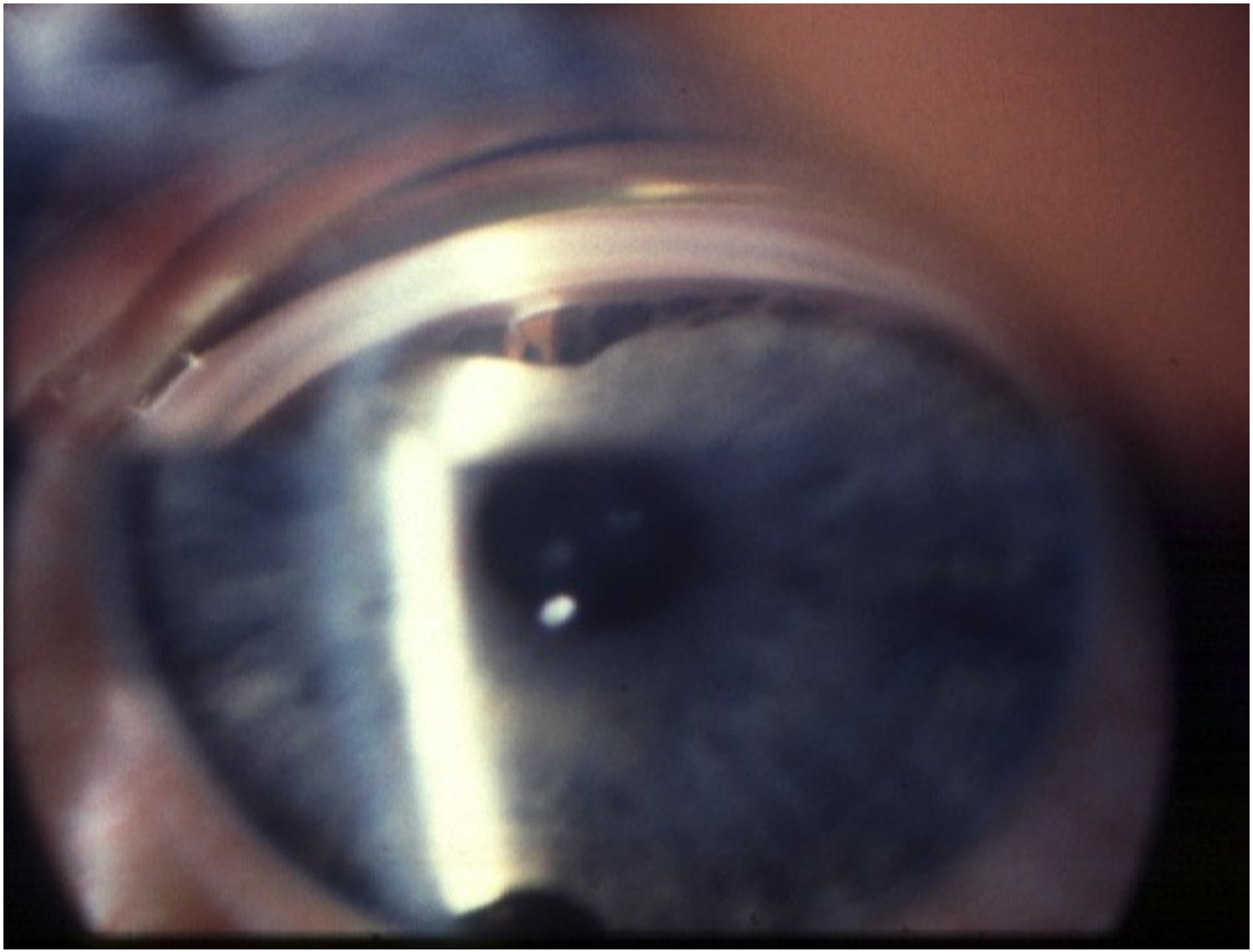

Raptured Globe

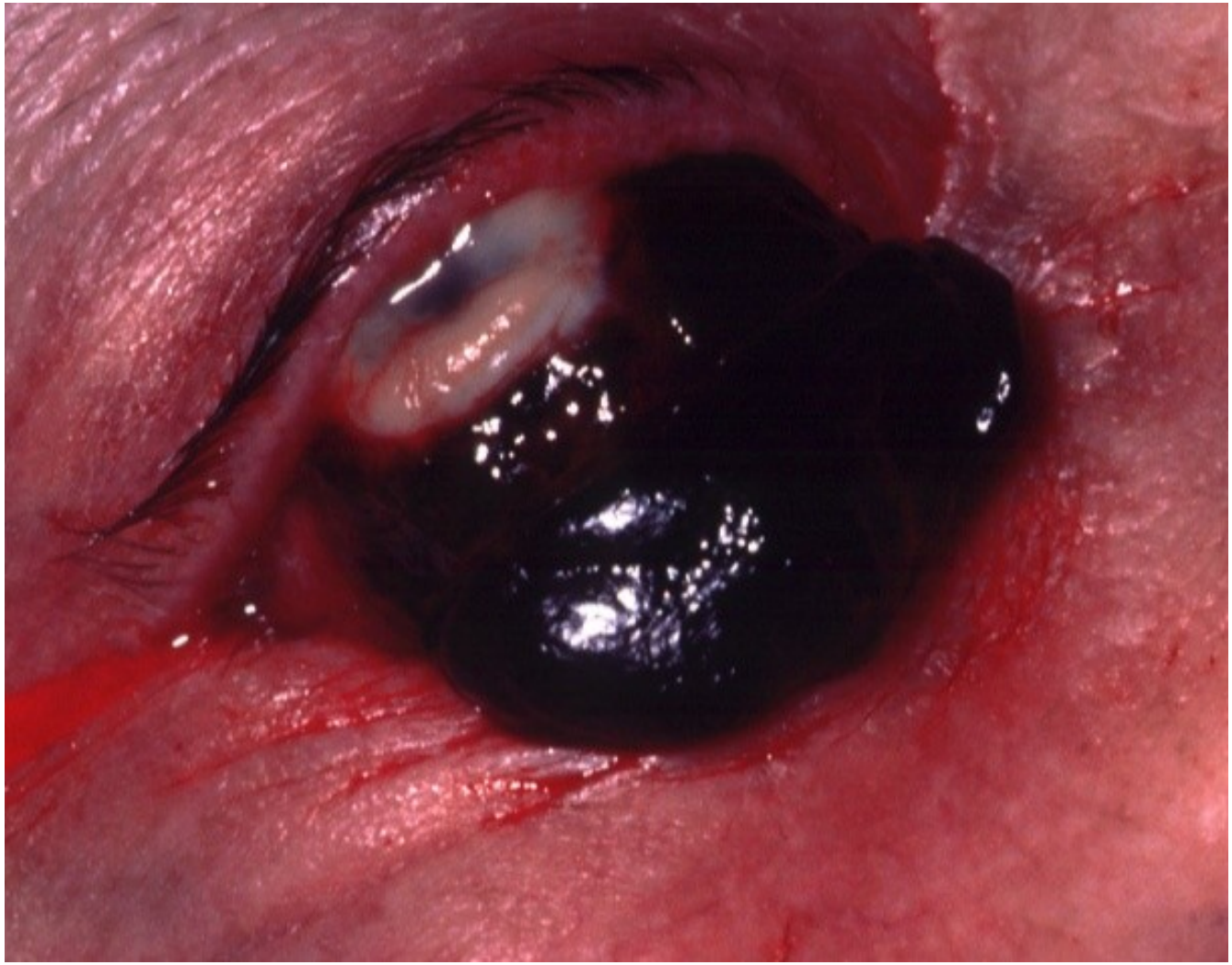

Posterior segment complications of blunt trauma

INCLUDE

- Commotio retinae/ Berlin’s edema
- Choroidal rupture and hemorrhage
- Avulsion of vitreous base and retinal dialysis
- Equatorial tears
- Macular hole
- Optic neuropathy

Commotio retinae

Choroidal rupture and haemorrhage

Equatorial tears

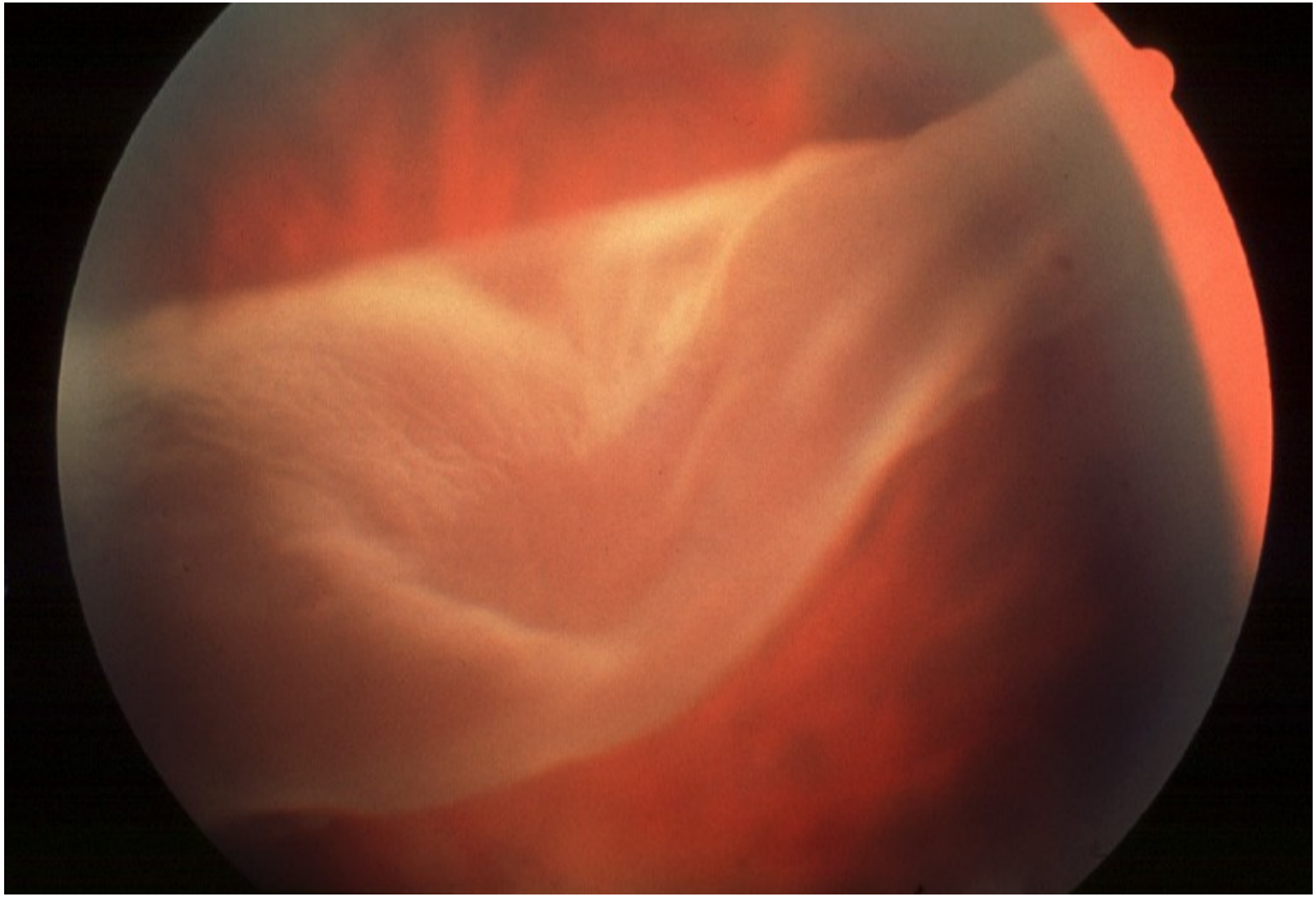

Avulsion of vitreous base/retinal dialysis

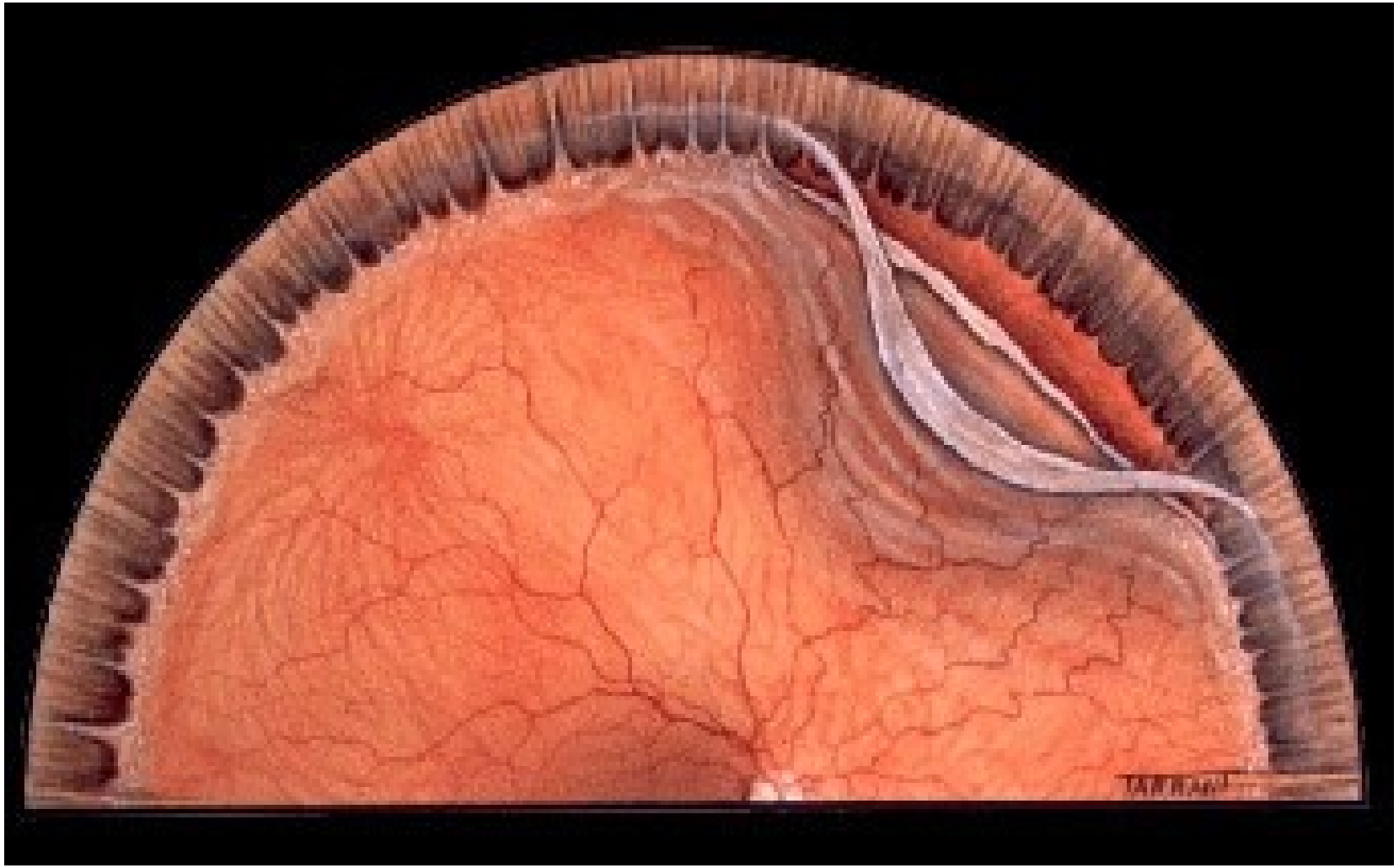

Macular hole

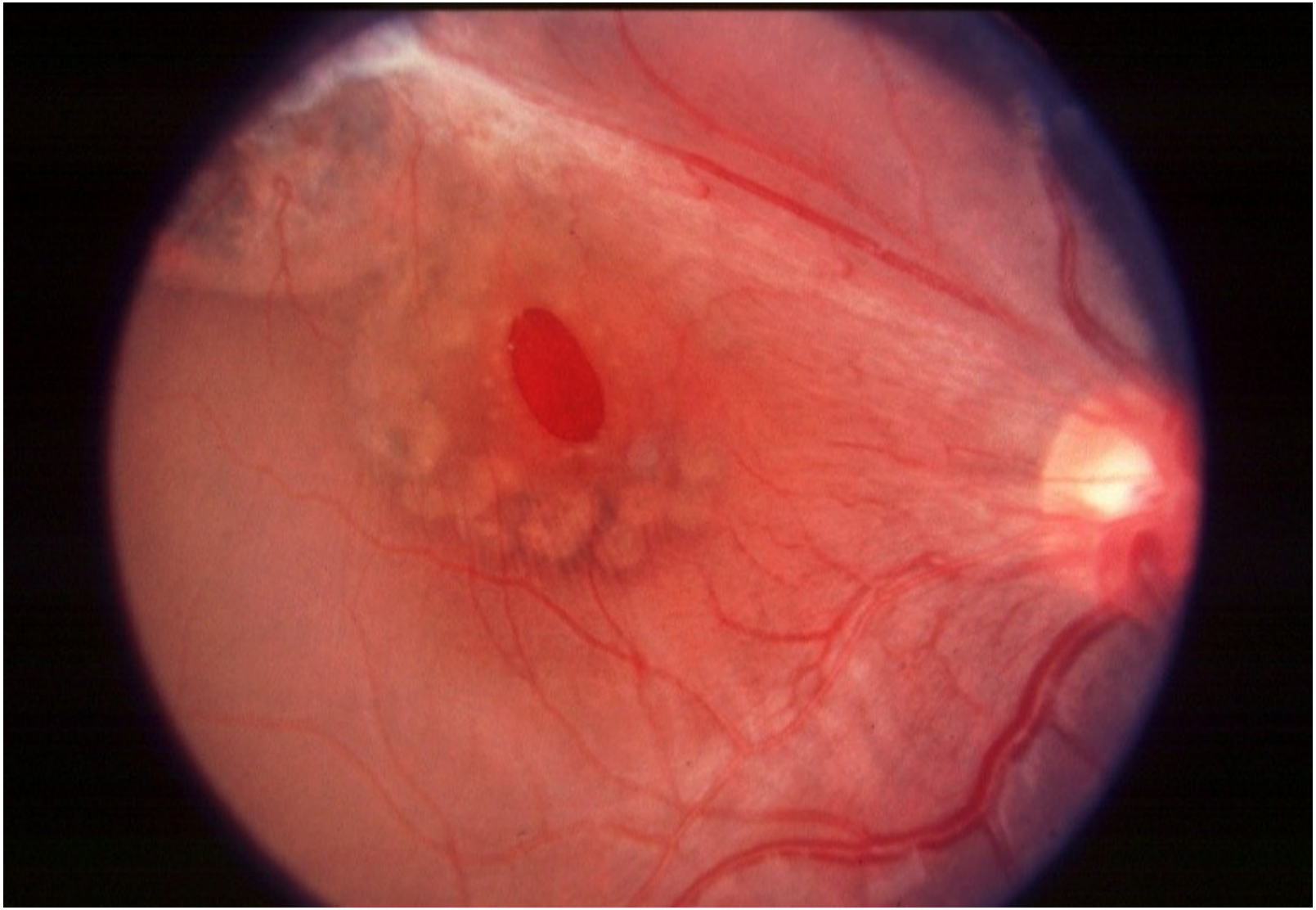

Optic neuropathy

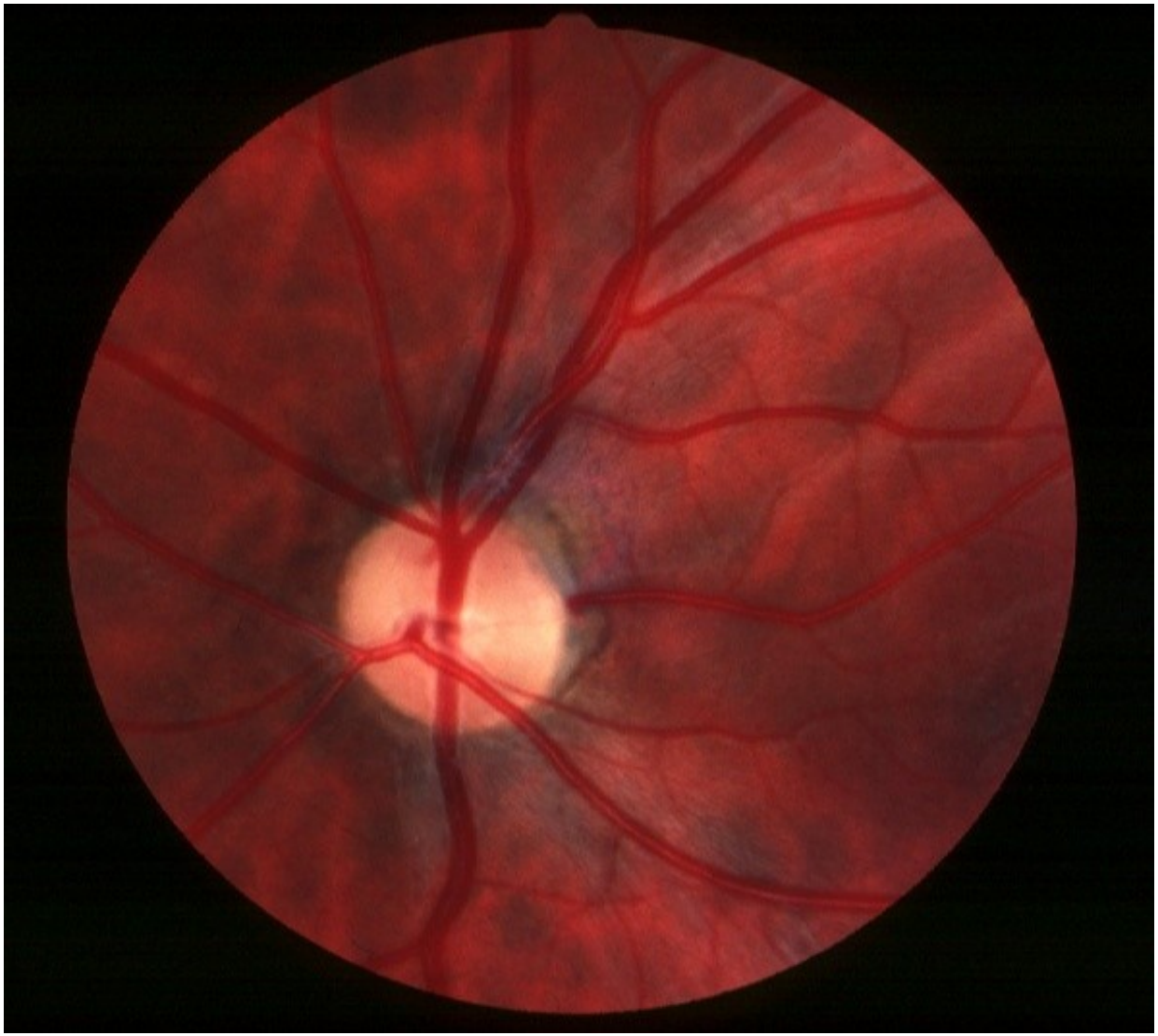

COMPLICATIONS OF PENETRATING TRAUMA

- Flat anterior chamber
- Uveal prolapse
- Damage to lens and iris
- Vitreous hemorrhage
- Tractional retinal detachment
- Endopthalmitis (hypopion)

Intraocular foreign bodies

Management of intraocular foreign bodies

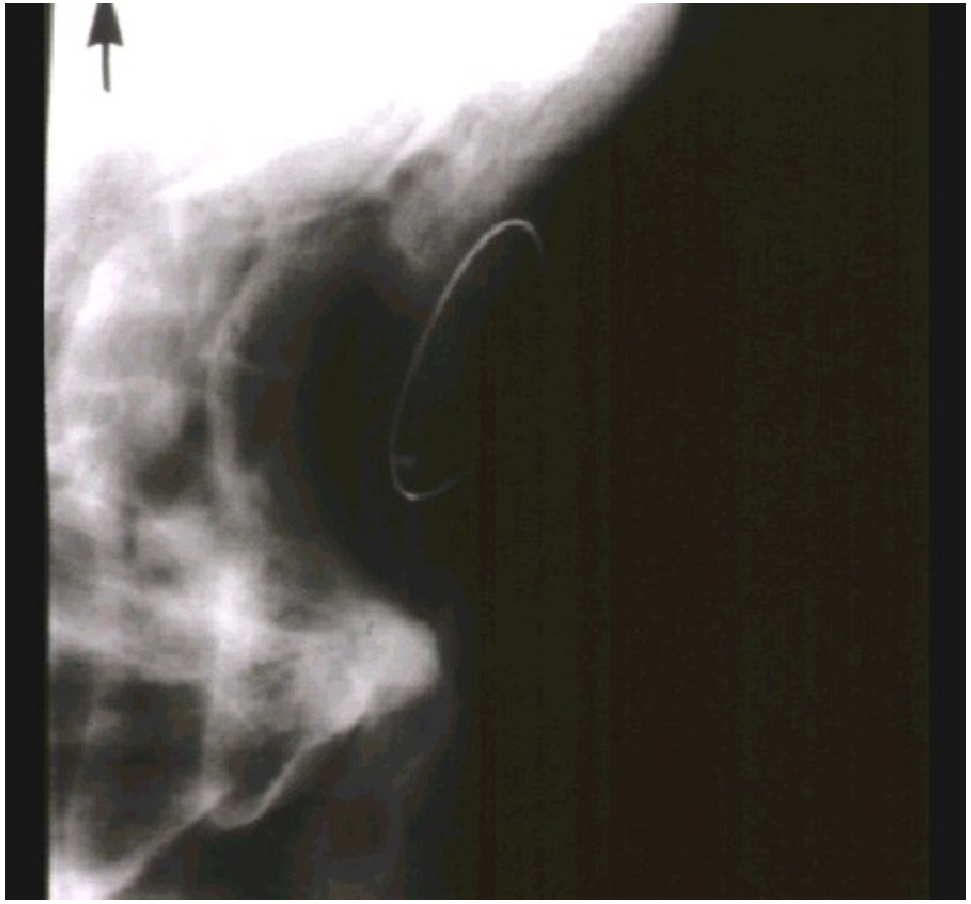

Localization with reference to radio-opaque marker

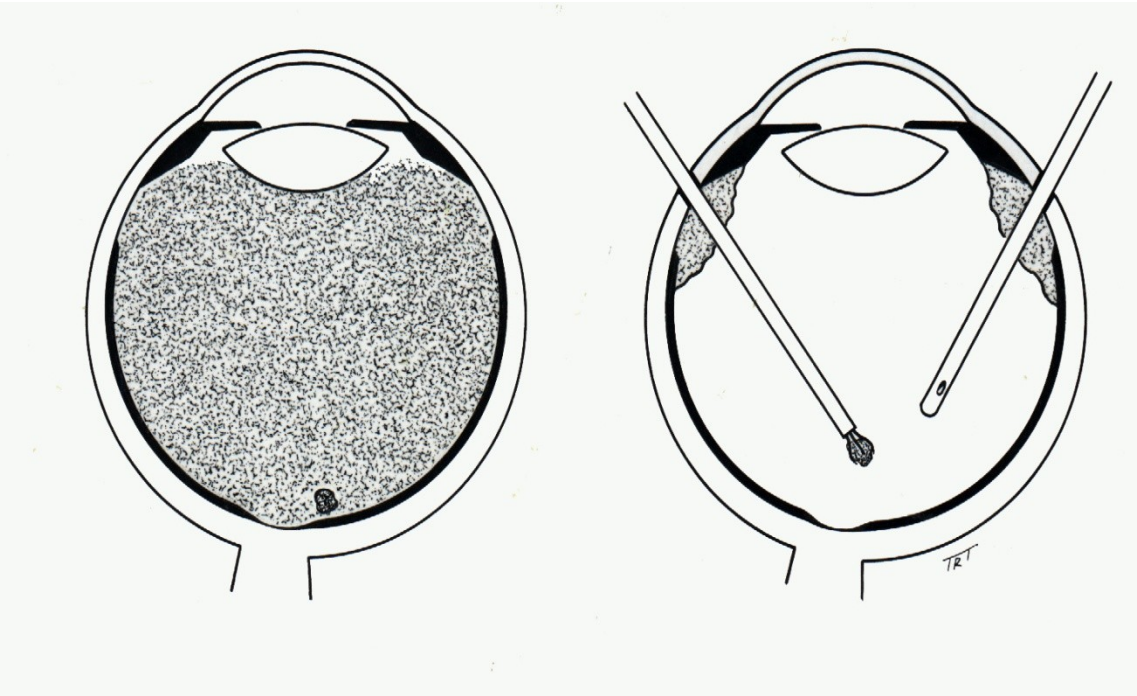

Removal with magnet or by pars plana vitrectomy

Chemical Injuries

Chemical Injuries.....

- Causes
  - Alkali Burns
    - Ammonia: fertilizers,refigerants,cleaning agents
    - Magnisium Hydrochloride: sparklers, flares
    - Lime: plaster,motor,cement,whitewash
    - Lye: drain cleaners
  - Acid Burns
    - Sulphuric acid: battery acid, burns on cornea and conjuntiva
    - Sulfurous acid: preservative (fruit/vegetable),bleach,refrigerant
    - Hydrofluoric acid:
    - Hydrochloric acid
    - Nitrous acid
    - Acetic acid

Grading of severity of chemical injuries

Grade I (excellent prognosis)

- Clear cornea
- Limbal ischaemia - nil

Grade II (good prognosis)

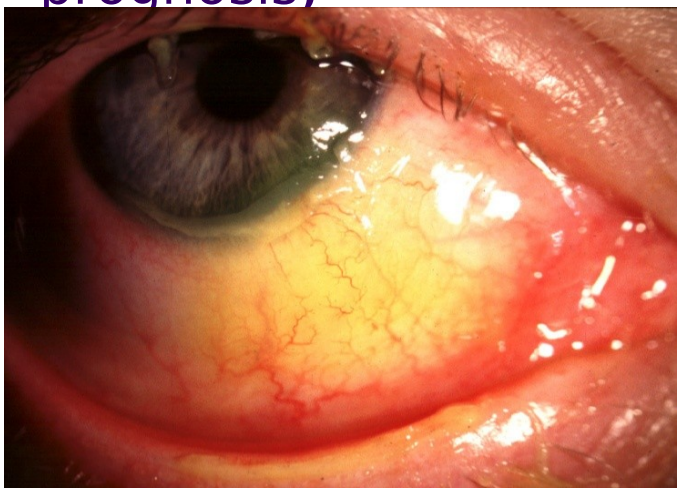

- Cornea hazy but visible iris details
- Limbal ischaemia < 1/3

Grade III (guarded prognosis)

- No iris details
- Limbal ischaemia - 1/3 to 1/2

Grade IV (v. poor prognosis)

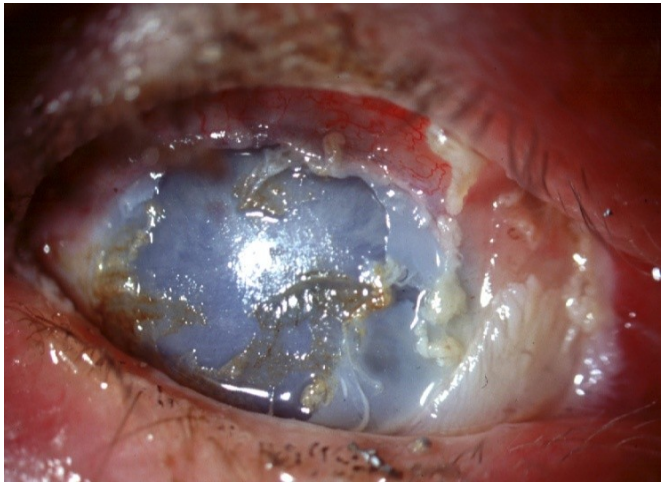

- Opaque cornea
- Limbal ischaemia > 1/2

Chemical Injuries.....

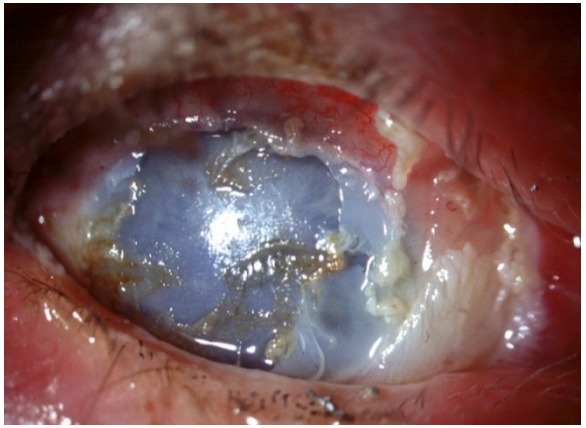

- Medical Treatment

Initial primary therapy

- Copious irrigation (15-30 min) - to restore normal pH
- Remove particulate matter
- Debride devitalized tissue
- Topical steroids (first 7-10 days) - to reduce inflammation
- Topical and systemic ascorbic acid - to enhance collagen production
- Topical citric acid - to inhibit neutrophil activity
- Topical and systemic tetracycline - to inhibit collagenase and neutrophil activity

Chemical Injuries.....

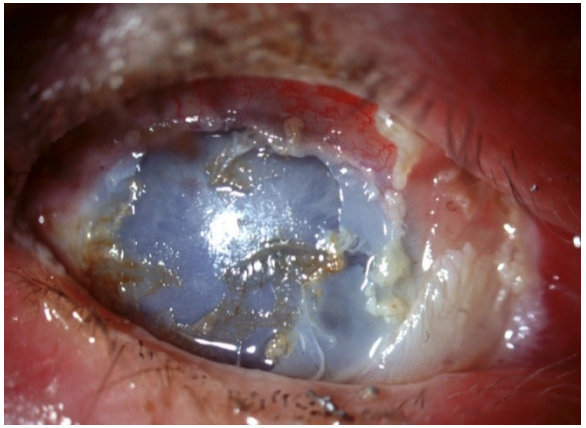

- Medical Treatment.....

Promote epithelial wound healing:

- Tear substitutes
- Puntal occlusions
- Therapeutic contact lens
- Ocular surface transplant

Chemical Injuries.....

Surgical treatment

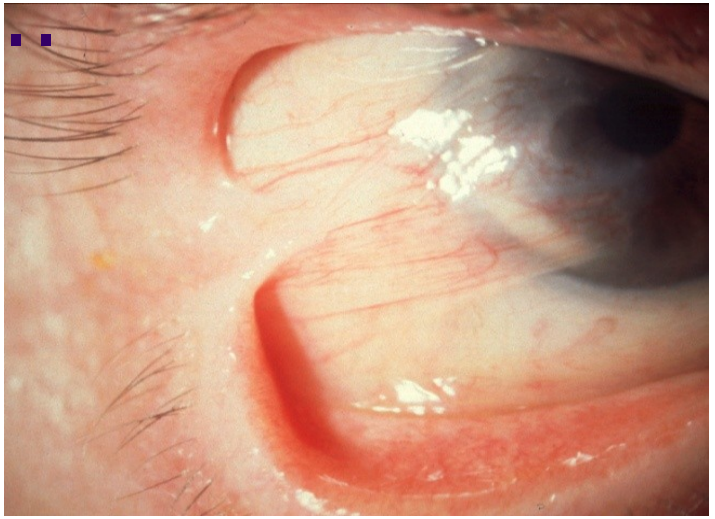

Division of conjunctival bands

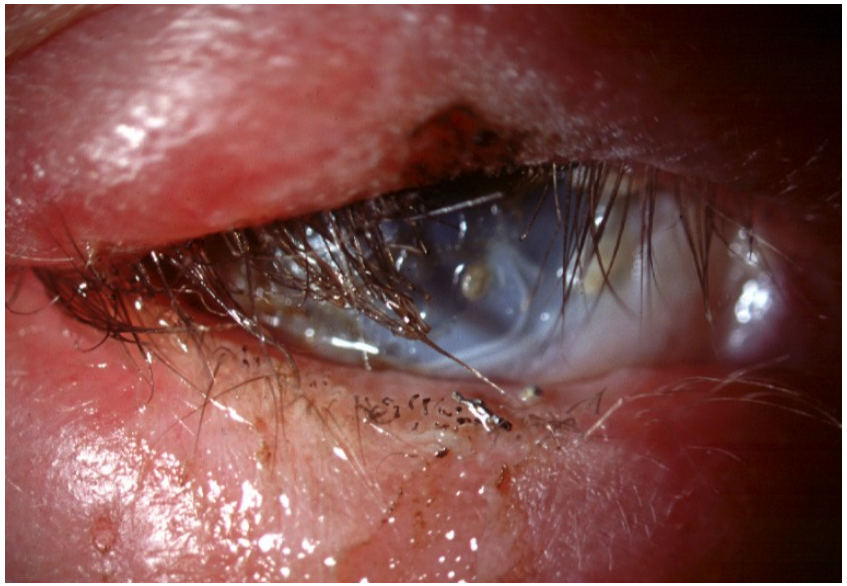

Correction of eyelid deformities

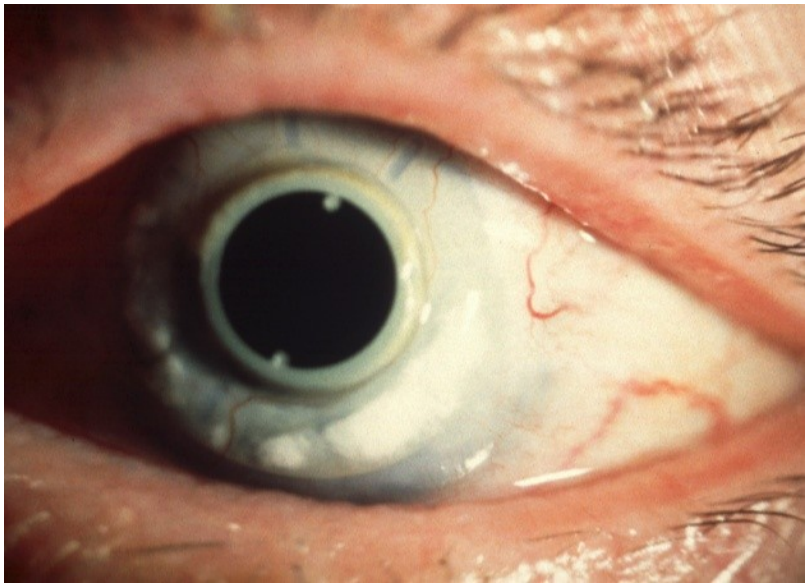

Treatment of corneal opacity by keratoplasty or keratoprosthesis

Medico-legal issues

- Sources of litigation
- Informed consent
- Diagnosis - delay & failure
- Purpose
- Treatment alternatives & risks
- Medical records

Bad medical results in good malpractice cases!!